

JOURNAL OF  
MANIPULATIVE  
AND  
PHYSIOLOGICAL  
THERAPEUTICS



Dedicated to  
the Advancement of  
Chiropractic Health Care  
Principles and Practice

Volume 33

Number 8


October 2010

ISSN 0161-4754

 **National**  
University of Health Sciences

 **ACA** The Official Scientific Journal of  
the American Chiropractic Association

\*\*\*\*\*5-DIGIT 80031  
42743 1076 V33#8  
TERRY R YOCHUM DC, DACBR  
10386 TENNISON CT  
WESTMINSTER CO 80031-2320  
MPT1  
P034  
002524



# LUMBAR DISK PROTRUSION RATES OF SYMPTOMATIC PATIENTS USING MAGNETIC RESONANCE IMAGING

John W. Gilbert, MD,<sup>a</sup> J. Chad Martin, DC,<sup>b</sup> Greg R. Wheeler, MD,<sup>c</sup> Benjamin B. Storey, MD,<sup>d</sup> Gregory E. Mick, DO,<sup>c</sup> Gay B. Richardson, MD,<sup>e</sup> Stephanie L. Herder, MD,<sup>c</sup> Kwadwo Gyarteng-Dakwa, MD,<sup>f</sup> and Patricia G. Broughton, ARNP<sup>g</sup>

## ABSTRACT

**Objective:** The purpose of this study was to determine the rate of disk protrusions detected via magnetic resonance imaging (MRI) in patients symptomatic for spine pain, radiculopathy, or other spine-related pain.

**Methods:** A retrospective review of 1983 MRI scans was performed over a 2-year period on 1486 patients, each of whom was symptomatic for spine pain, radiculopathy, or other noncancer, spine-related pain. Of these patients, 761 were scanned in the recumbent position using low-field (0.3 T, Airis II, Hitachi, Twinsburg, Ohio) MRI, and 725 were scanned in an upright, sitting position using mid-field (0.6 T) open Upright MRI (Fonar, Melville, NY). In total, 986 serial scans were performed on patients in the recumbent position and 997 serial scans on patients in the weight-bearing position.

**Results:** One or more disk protrusions were identified in 73.3% of scans performed in the sitting position and in 50.1% of scans performed in the recumbent position. Most disk protrusions occurred at L5-S1 (52.3% and 29.8%), L4-L5 (42.6% and 26.7%), and L3-L4 (26.7% and 13.1%) in upright and recumbent positions, respectively.

**Conclusions:** The disk protrusion rate in this group of patients ranged between 50.1% (recumbent) and 73.3% (weight-bearing). These rates are higher than rates reported in the medical literature for asymptomatic patients, a finding that supports the decision to further evaluate patients with persistent spine-related pain. (*J Manipulative Physiol Ther* 2010;33:626-629)

**Key Indexing Terms:** *Intervertebral Disk Displacement; Magnetic Resonance Imaging; Spine*

Cases of chronic spine pain, radiculopathy, and other noncancer spine-related pain are the most frequent and most difficult that the spine care professional is called upon to treat.<sup>1</sup> One common source of pain is lumbar disk protrusion. Lumbar disk protrusions are associated with degenerative disk disease and lumbar spondylosis. Fortunately, degenerative disk disease and lumbar spondylosis caused by normal aging of the human spine are usually asymptomatic.<sup>2</sup> For symptomatic individuals, magnetic resonance imaging (MRI) is the preferred diagnostic tool for determining the extent of disk protrusion.<sup>3</sup> There are a variety of MRI technologies in use today. Traditional MRI involves scanning the patient in the recumbent position, typically using a low-strength (0.3 T) magnetic field. In

contrast, next-generation, open MRI technology allows for scanning patients in dynamic, weight-bearing positions; this technology typically uses a mid-strength (0.6 T) magnetic field.

Of the asymptomatic individuals, 16% to 33% have been shown to have lumbar disk protrusions upon MRI in the recumbent position.<sup>4-7</sup> In contrast, few information is available about the rate of disk protrusion in symptomatic patients. The purpose of this study was to compare the rate of disk protrusions detected via MRI in a relatively large population of patients symptomatic for spine pain, radiculopathy, or other noncancer spine-related pain against the rate of disk protrusions on MRI in asymptomatic patients as reported in the medical literature.

<sup>a</sup> Neurosurgeon and Neuroimager, Spine and Brain Neurosurgical Center, Lexington, Ky.

<sup>b</sup> Chiropractor and Medical Student, Pikeville College, School of Osteopathic Medicine, Pikeville, Ky.

<sup>c</sup> Neurosurgeon, Spine and Brain Neurosurgical Center, Lexington, Ky.

<sup>d</sup> Psychiatrist, Spine and Brain Neurosurgical Center, Lexington, Ky.

<sup>e</sup> Physiatrist, Spine and Brain Neurosurgical Center, Lexington, Ky.

<sup>f</sup> Anesthesiologist, Spine and Brain Neurosurgical Center, Lexington, Ky.

<sup>g</sup> Nurse Practitioner, Spine and Brain Neurosurgical Center, Lexington, Ky.

Submit requests for reprints to: John W. Gilbert, MD, Spine and Brain Neurosurgical Center, PO Box 22430, Lexington, KY 40522-2430 (e-mail: [correspondence@sbn cmd.com](mailto:correspondence@sbn cmd.com)).

Paper submitted January 29, 2010; in revised form August 3, 2010; accepted August 11, 2010.

0161-4754/\$36.00

Copyright © 2010 by National University of Health Sciences.

doi:10.1016/j.jmpt.2010.08.010

URL: <http://www.sbn cmd.com>.

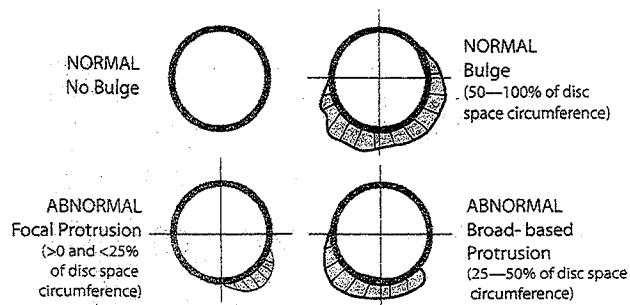
## METHODS

We conducted a retrospective study by reviewing 1983 serial magnetic resonance images from scans that had been performed over a 2-year period (2006-2007) on a total of 1486 patients, each of whom was symptomatic for spine pain, radiculopathy, or other spine-related noncancer pain that was unresolved after conservative treatment. All patients had been physician-referred to our private, multi-specialty neuroscience practice. New patients who had already undergone MRI for their condition with another health care provider and patients who requested their MRI be performed at an alternative facility were not included in this study. After the procedure was explained to the patient, written consent for use of their deidentified medical data for research purposes was obtained.

A comprehensive medical history was obtained from each patient, after which a detailed or focal neurologic examination was performed by the medical staff and physicians at 1 of our 5 offices located in central and eastern Kentucky. Most patient visits were for non-MRI medical services such as consults, preoperative and postoperative care, injection therapies, pain pump refill or check, or behavioral health evaluations. The medical staff and practice physicians use pain program accreditation guidelines as well as our own peer-reviewed, published guidelines in assessing and managing the most common types of pain associated with symptomatic disk protrusions and other causes of chronic noncancer pain.<sup>1,8,9</sup> Indication for MRI was based on current evidence-based recommendations.<sup>3</sup> After obtaining pre-certification for the lumbar MRI, imaging was performed at the practice location of the patient's choice.

Of our 5 offices, 3 were equipped with a mid-field (0.6 T) Upright MRI (Fonar Corp, Melville, NY), which allows imaging of the patient in the weight-bearing, sitting position. The remaining 2 offices were equipped with the Airis II (Hitachi Medical Systems, Twinsburg, Ohio) low-field (0.3 T) recumbent MRI scanner. All of our MRI machines were accredited by the American College of Radiology.<sup>10</sup> A high-definition computer workstation using Radworks technology (GE Healthcare, Buckinghamshire, England) was available at each office facility; offices were linked using secure intranet encrypted T lines so images could be reviewed by the distance neuroradiologist, radiologist, or neuroimaging physician.

On the day of the MRI examination, the patient completed a comprehensive MRI intake form and questionnaire. The MRI technologists at each location reviewed potential contraindications for imaging with the radiologist or neuroimaging physician. All images were reviewed and interpreted. Experienced readers using standardized nomenclature are known to have moderate or greater agreement when interpreting disk protrusion.<sup>11</sup> Nomenclature and classification of lumbar disk pathology used the definition of protrusion (a herniated disk) as any extension of disk tissue



**Fig 1.** Schematic of MRI slices through disk space that does or does not meet the diagnostic criteria used in this study for disk protrusion.

beyond the edges of the apophyses that intersects greater than 0% and less than 25% of the disk space circumference (focal protrusion) or intersects 25% to 50% of the disk space circumference (broad-based protrusion). In contrast, a disk bulge was defined as either no extension of the disk tissue or an extension of disk tissue that intersects 50% to 100% of the disk space circumference (Fig 1).<sup>12</sup> Disk protrusion is an abnormal condition, whereas disk bulge is normal.

The review of all radiologic, neuroimaging, or neuroradiologic reports was performed by a single individual. Although persons interpreting data should ideally be blinded to minimize the introduction of bias, blinding in this study was precluded because images originating from different locations were identifiable by the type of scanner used due to inherent differences in the recumbent and Upright MRI technologies as follows: (1) software packages, (2) image formats, and (3) the larger field-of-views of the Fonar vs the Hitachi equipment.

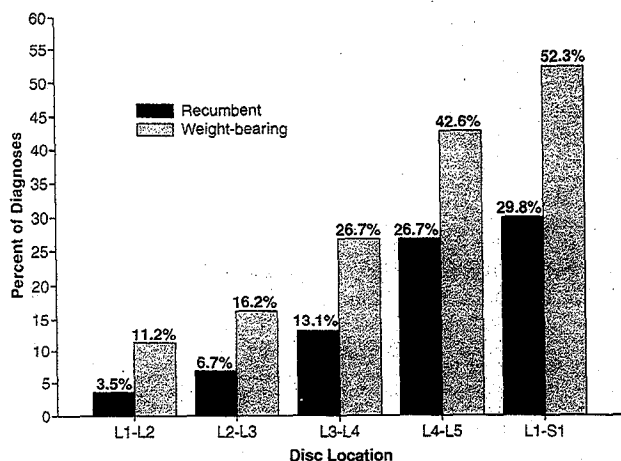
Of the 1486 symptomatic patients, 761 (48.9% women, aged 9-94 years; 51.1% men, aged 24-104 years) underwent scanning in the recumbent position at 1 of the 2 clinics equipped with an Airis II MRI scanner. A total of 725 patients (50.4% women, aged 18-86 years; 49.6% men, aged 13-82 years) underwent imaging at 1 of the 3 clinics equipped with a weight-bearing Upright MRI scanner.

Over the 2-year period, of the 1983 serial scans performed, a total of 986 scans (48.9% on women, 51.1% on men) were performed on the patients in the recumbent position and 997 scans (49.9% on women; 50.1% on men) were performed on patients in a sitting, weight-bearing position.

In view of the inherent differences between the Airis and Upright technologies, results using these techniques were separately summed and expressed as percentiles.

## RESULTS

From the 3 clinics using the weight-bearing Upright MRI, one or more disk protrusions were identified in 73.3% of the scans. At the remaining 2 clinics that used traditional



**Fig 2.** Percentages of disk protrusions by location in symptomatic patients as identified using low-field strength (0.3 T) MRI in the recumbent (non-weight-bearing) or mid-field strength (0.6 T) MRI in the sitting (weight-bearing) position.

recumbent MRI technology, one or more disk protrusions were identified in 50.1% of the scans.

Of the 997 serial weight-bearing scans, disk protrusions occurred as follows: 112 (11.2%) at L1-L2, 161 (16.2%) at L2-L3, 265 (26.7%) at L3-L4, 425 (42.6%) at L4-L5, and 521 (52.3%) at L5-S1 (Fig 2). Of the 986 recumbent scans, disk protrusions were identified as follows: 35 (3.5%) at L1-L2, 68 (6.7%) at L2-L3, 129 (13.1%) at L3-L4, 263 (26.7%) at L4-L5, and 294 (29.8%) at L5-S1 (Fig 2).

## DISCUSSION

Disk protrusion rates in patients symptomatic for spine pain, radiculopathy, or other noncancer spine-related pain were substantially higher (50.1%-73.3%) than those previously reported for asymptomatic patients (ie, 16%-33%), which were performed in the recumbent position.<sup>4-7</sup> This finding reinforces the value of testing for protrusions in patients who exhibit spine pain, radiculopathy, or other noncancer spine-related pain and who have failed conservative treatments such as physical therapy, chiropractic therapy, or osteopathic therapy. As expected, most disk protrusions occurred at L5-S1 (weight-bearing, 52.3%; recumbent, 29.8%), followed by L4-L5 (weight-bearing, 42.6%; recumbent, 26.7%) and then followed by L3-L4 (weight-bearing, 26.7%; recumbent, 13.1%). These findings are consistent with reports by Greenberg<sup>13</sup> that the L4-L5 and L5-S1 vertebrae account for most of the cases of herniated lumbar disks.

## Limitations

Limitations of this study include that the sample of patients were self-selected to our specialty clinic therefore may not necessarily represent other patients with spine pain. As well, this was a retrospective chart review; thus, there may have

been some bias due to the time frame the cases were drawn from and from the interpretation of the MRI by the authors.

Of note, at each spinal location, symptomatic patients imaged in a sitting, weight-bearing position had a higher rate of disk protrusion compared with symptomatic patients imaged in the recumbent position. Lumbar disk space pressure is known to vary with body position, being lowest in the recumbent position, slightly higher in the standing position, and highest in the sitting position.<sup>8</sup> These pressure differences have been shown to translate into differences in severity of disk protrusion on MRI.<sup>9</sup> However, because there was no funding to perform scans on patients in both positions at the same points in time, no valid comparison is possible between these technologies here. Furthermore, because the magnetic field strength between these 2 MRI technologies differs, we cannot conclude that all of the observed difference in disk protrusion rate is attributable to the position of the patient at the time of scanning.

Our results are similar to our previous observations<sup>8,14-16</sup> and those of Panjabi<sup>17</sup> that suggest that among symptomatic patients, weight-bearing MRI may more likely be positive for disk protrusion than recumbent MRI. How these 2 technologies differ in their ability to diagnose disk protrusion in symptomatic patients is not known. Jinkins and other investigators<sup>18-22</sup> have noted that potential benefits of weight-bearing MRI include the provision of valuable information regarding a variety of other spinal disorders and the revealing of occult disease. Until more is learned, if an MRI scan performed in the recumbent position is negative for disk protrusion and inconsistent with the physical examination or medical history of the patient, the physician may want to consider whether a follow-up weight-bearing (sitting position) MRI would be of value. Prospective studies of the differences between results obtained using recumbent and weight-bearing MRI technologies are needed.

## CONCLUSION

The disk protrusion rate among these patients who were symptomatic for spine pain, radiculopathy, or other noncancer spine-related pain ranged between 50.1% (recumbent) and 73.3% (weight-bearing). These rates are substantially higher than rates reported in the medical literature for asymptomatic patients. This finding may support the decision to test for disk protrusion in patients with persistent spine-related pain.

### Practical Application

- Disc protrusion rates on MRI in either the recumbent or weight-bearing positions were found to be higher in patients symptomatic for spine-related pain compared with cited rates in asymptomatic individuals.

## FUNDING SOURCES AND POTENTIAL CONFLICTS OF INTEREST

No funding sources or conflicts of interest were reported for this study.

## REFERENCES

1. Gilbert JW, Wheeler GR, Lingreen RA, et al. The ten Cs of chronic noncancer pain: universal precautions for the chronic noncancer pain patient. *Am J Pain Manage* 2005; 15:22-32.
2. Podichetty V. The aging spine: the role of inflammatory mediators and intervertebral disc degeneration. *Cell Mol Biol* 2007;53:4-18.
3. United Healthcare: A United Health Group Company. Physician guidelines: Current evidence-based recommendations regarding imaging. Lexington Kentucky; 2006.
4. Borenstein DG, O'Mara JW, Boden SD, et al. The value of magnetic resonance imaging of the lumbar spine to predict low-back pain in asymptomatic subjects: a seven-year follow-up study. *J Bone Joint Surg Am* 2001;83-A:1306-11.
5. Jensen MC, Brant-Zawadzki MN, Obuchowski N, Modic MT, Malkasian D, Ross JS. Magnetic resonance imaging of the lumbar spine in people without back pain. *N Engl J Med* 1994; 331:69-73.
6. Stadnik T, Lee R, Coen H, Neirynek E, Buisseret T, Osteaux M. Annular tears and disc herniation: prevalence and contrast enhancement on MR images in the absence of low back pain or sciatica. *Radiology* 1998;206:49-55.
7. Weishaupt D, Zanetti M, Hodler J, Boos N. MR imaging of the lumbar spine: prevalence of intervertebral disk extrusion and sequestration, nerve root compression, end plate abnormalities, and osteoarthritis of the facet joints in asymptomatic volunteers. *Radiology* 1998;209:661-6.
8. Gilbert J. Letter to the Editor: Ten Cs of Chronic Noncancer Pain. *Am J Pain Manage* 2005;15:45-7.
9. Gilbert JW, Wheeler GR, Lingreen RA, Scheiner SJ, Upadhyay SP, Gyarteng-Dakwa K. Compliance in chronic noncancer pain patients on long-acting opiates, short-acting opiates, or non-opiates. *Am J Pain Manage* 2006;16:121-7.
10. American College of Radiology. Accreditation [online]. In: Available at: <http://www.acr.org/accreditation.aspx>2008. 2008.
11. Brant-Zawadzki M, Jensen MC, Obuchowski N, Ross S, Modic MT. Interobserver and intraobserver variability in interpretation of lumbar disc abnormalities: a comparison of two nomenclatures. *Spine* 1995;20:1257-63.
12. American Society of Neuroradiology American Society of Spine Radiology North American Spine Society Corporate. Nomenclature and classification of lumbar disc pathology [online]. Available at: [www.asnr.org/nomenclature/recommendations.asp](http://www.asnr.org/nomenclature/recommendations.asp)2001.
13. Greenberg MS. Handbook of neurosurgery. 2th ed. Lakeland (Fla): Greenberg Graphics, Inc; 1991. p. 406.
14. Gilbert J, Wheeler G, Lingreen RA, Johnson R, Scheiner SJ, Gibbs RD. Upright weight-bearing cervical flexion/extension dynamic magnetic resonance imaging: case report and review of the literature. *Eur J Radiol Extra* 2006;60:121-4.
15. Gilbert JW, Wheeler GR, Lingreen RA, et al. Imaging in the position that causes pain. *Surg Neurol* 2008;69:463-5.
16. Moazzaz P, Hong SW, Miyazaki M, Ashkan M, Wang J. Positional MRI: a valuable tool in the assessment of cervical disc bulge. *Spine J* 2007;7:S38-39.
17. Panjabi MM, Pelker RR, White AA. Biomechanics of the spine. In: Wilkins RH, Rengachary SS, editors. *Neurosurgery*. New York: McGraw-Hill; 1985. p. 2219-22.
18. Ferreiro-Perez A, Garcia Isidro M, Ayerbe E, Castedo J, Jinkins JR. Evaluation of intervertebral disc herniation and hypermobile intersegmental instability in symptomatic adult patients undergoing recumbent and upright MRI of the cervical and lumbosacral spines. *Eur J Radiol* 2007;62:444-8.
19. Hirasawa Y, Bashir W, Smith F, Magnusson M, Pope M, Takahashi A. Postural changes of the dural sac in the lumbar spines of asymptomatic individuals using positional stand-up magnetic resonance imaging. *Spine* 2007;32:E136-140.
20. Jinkins JR, Dworkin J. Proceedings of the State-of-the-Art Symposium on Diagnostic and Interventional Radiology of the Spine, Antwerp, September 7, 2002 (Part two). Upright, weight-bearing, dynamic-kinetic MRI of the spine: pMRI/kMRI. *JBR-BTR* 2003;86:286-93.
21. Willen J, Danielson B, Gaultz A, Niklason T, Schönström SN, Hansson T. Dynamic effects on the lumbar spinal canal: axially loaded CT-myelography and MRI in patients with sciatica and/or neurogenic claudication. *Spine* 1998;23: 1506-7.
22. Willen J, Danileson B. The diagnostic effect from axial loading of the lumbar spine during computed tomography and magnetic resonance imaging in patients with degenerative disorders. *Spine* 2001;26:2607-14.